

DISCREPANCY IN ULTRASOUND BIOMETRIC PARAMETERS OF THE HEAD (HC - HEAD CIRCUMFERENCE, BPD - BIPARIETAL DIAMETER) IN BREECH PRESENTED FETUSES

Marek Lubusky^{a, b*}, Martin Prochazka^a, Martina Langova^a, Katherine Vomackova^a,
Ludek Cizek^c

^a Department of Obstetrics and Gynecology, Palacký University, Teaching Hospital, Olomouc, Czech Republic

^b Department of Medical Genetics and Fetal Medicine, Palacký University, Teaching Hospital, Olomouc, Czech Republic

^c Department of Preventive Medicine, Palacký University, Olomouc, Czech Republic

e-mail: lubusky@email.cz

Received: August 15, 2007; Accepted: September 15, 2007

Key words: Breech presentation/Ultrasound/Fetal head/Biometry/Breech head/ Dolichocephaly

Background: A comparison of fetal ultrasonographic biometric parameters of the head (head circumference - HC, biparietal diameter - BPD) in breech presented fetuses.

Methods: Ultrasound biometry was performed in accordance with the method presented in the reference tables. In all breech presented fetuses, the HC, BPD and FL (femur length) were measured. High-risk and multiple pregnancies were excluded from the study.

Results: A total of 111 ultrasonographic biometries were performed between the 31st - 38th week of gestation. Fetuses in the breech position had a significantly lower BPD compared to HC and FL. The difference between BPD and HC was 16.2 days (95%CI 14.3-18.1; p = 0.001). Maternal age at delivery was 20 - 36 years (average 28.1; median 28.0).

Conclusions: According to our results, fetuses in the breech position have a significantly lower BPD compared to HC or FL. HC and FL parameters correlate with gestational age. In cases of ultrasonographic biometric discrepancy between BPD and FL, the fetal position should be taken into account. **Breech-presented fetuses have an elongated head shape and ultrasound biometrics should evaluate its circumference (HC). It is important to responsibly interpret the results so as not to stress the expecting mother with suspicions of fetal pathology.**

INTRODUCTION

Ultrasonographic fetal biometry is the most widespread method used to establish gestational age, estimate fetal size and monitor its growth. BPD and HC measurements are performed routinely during the prenatal ultrasound screening in the third trimester of pregnancy.

However, baseline data for these head dimensions are constructed from a sample of the general obstetric population, and therefore include only a minority of fetuses in the breech position in the third trimester. Such a subgroup may have significantly different head dimensions which may not significantly affect the distribution of values for the population sample; however, extrapolation from this sample to an individual of such a subgroup could lead to serious error.

The BPD in a normally growing fetus presented in the breech position is frequently much less than what is anticipated based on gestational age. This small BPD is consistent with the description of the "breech head" by Haberkern et al.¹ who used the term to denote scaphocephaly, a prominent occiput and an occipital shelf. Scaphocephaly, however, implies premature fusion of the saggittal suture as the cause of an elongated skull which was not demonstrated in any of the eight babies described by Haberkern et al.¹. Dolichocephaly seems a

more appropriate term. Sunderland² has also drawn attention to the association between the breech position and occipital prominence, coining the term "hyptiocephaly". This feature was present in 29 of the 37 breech babies, an incidence of 78 %, but represents only one aspect of the "breech head" as described by Haberkern et al.¹.

The purpose of the study was to establish potential prenatal differences in biometric parameters of the fetal head (HC, BPD) in fetuses in the breech position.

MATERIALS AND METHODS

Ultrasound examinations were performed prospectively at the Department of Obstetrics and Gynecology and at the Department of Medical Genetics and Fetal Medicine at Palacký University Teaching Hospital in Olomouc. All the scans were performed transabdominally using 5-MHz transducers (GE Voluson 730 Expert, GE Healthcare Technologies, Zipf, Austria). Ultrasonographic measurements were performed using standard methodology.

Ultrasound biometry was performed in accordance with the method presented in the reference tables. In all breech-presented fetuses, the HC, BPD, AC (abdominal circumference) and FL were measured. Hadlock normograms³ were used to quantify the biometric parameters.

For a clear clinical interpretation, the corresponding gestational age for the individual parameters (HC, BPD, AC and FL) was expressed in days. The biometric parameter used to determine gestational age was femur length, which is not gender-dependent⁴⁻⁶, and in all our cases it correlated with the first trimester ultrasound biometry (crown-rump length - CRL). Growth retarded fetuses and high-risk or multiple pregnancies were excluded from the study. All the measurements were performed by one examiner.

Statistical analysis was performed using the Mann-Whitney *U*-test. All values with $p < 0.01$ were considered statistically significant.

RESULTS

A total of 111 ultrasonographic biometries were performed between the 31st-38th week of gestation. Fetuses in the breech position had a significantly lower BPD compared to HC. HC parameter correlated with gestational age. The difference between BPD and HC was 16.2 days (95 %CI 14.3-18.1; $p = 0.001$). The distributions of ultrasound examinations at different stages of gestation are shown in Fig. 1. Discrepancies in ultrasonographic biometric head parameters (HC, BPD) of fetuses in the breech position are demonstrated in Figs. 2 and 3. Maternal age at delivery was 20-36 years (average 28.1; median 28.0).

DISCUSSION

Fetuses in the breech position have a significantly smaller BPD compared to fetuses in the head-down position in the third trimester as well as postnatally⁷⁻⁹. This is caused by mild cranial deformation which occurs antepartally in at least one-third of fetuses in the breech position⁷. Features of this (mild) cranial deformation (dolichocephaly, a prominent occiput with a suboccipital shelf, an elongated face and a parallel-sided head) constitute the "breech head"^{1,7}. The caliper-determined occipitofrontal/biparietal diameter ratio (OFD/BPD) in these newborn infants is consistently above 1.3 (Figs. 3 and 4). This ratio, when calculated from ultrasound examination in the third trimester, was also found to correlate well with the "breech head" shape. Ultrasound identification of these babies should prevent the misdiagnosis of fetal growth retardation based on serial BPD measurements alone.

The term "breech head" in reference to the cranial deformity was first suggested by Haberker et al.¹ and implicates the most common etiology. The distinctive distortion of the cranium is presumably secondary to the forces applied to the growing cranium by the uterine fundus as the fetus is constrained in the breech position in late gestation, often with the head retroflexed. The term size, primiparity and oligohydramnios were recognized as additional factors predisposing to in utero constraint. In babies with "breech head" screened ultrasonographically by Kasby et al.⁷, the placental site was usually posterior

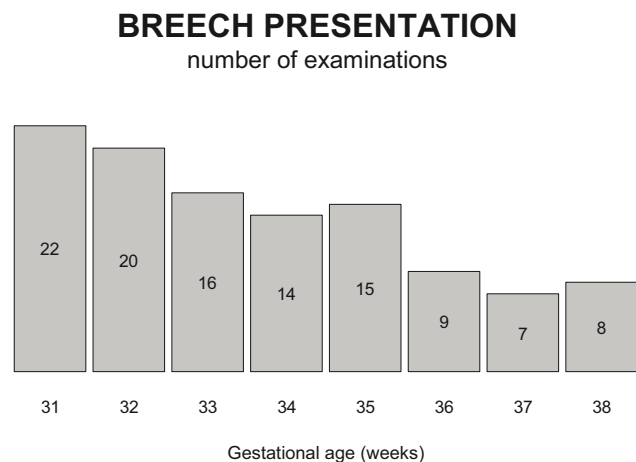


Fig. 1. Distribution of examinations in completed gestational weeks (n = 111).

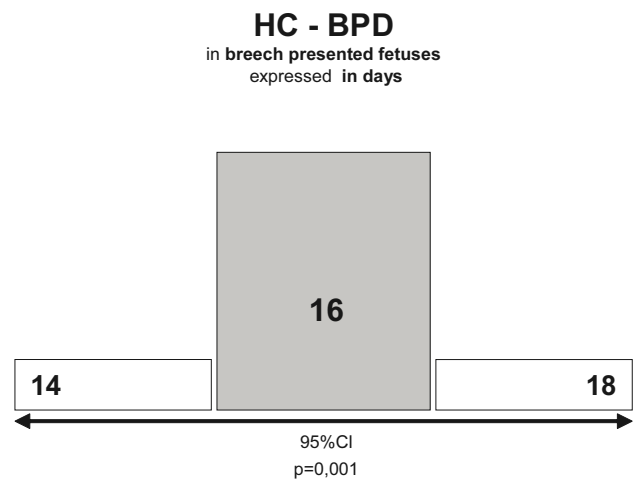


Fig. 2. Discrepancy of ultrasound biometric parameters of the head (HC - head circumference, BPD - biparietal diameter) in breech presented fetuses. BPD was significantly smaller compared to HC measurements. In the 31st - 38th week scans, estimated difference was 16.2 days (95%CI 14.3-18.1, $p = 0,001$).

and it is suggested that this leads to closer apposition of the fetal skull to the uterine fundus, which in turn can exert a compression effect. Once the constraint is relieved postnatally, the head shape has the potential for complete resolution. In itself, the deformation does not indicate an underlying calvarial or CNS structural malformation¹.

It is likely that the altered head shape is a reflection of intrauterine environmental factors and it suggests that the cranial abnormality under consideration is a postural deformation associated with the in utero breech position. It is not known how early the head deformation can occur, but we have ultrasound evidence of marked dolichocephaly in the breech fetus as early as 31 weeks.

The evidence presented as well as our results show that in a considerable proportion of breech babies the BPD is smaller than expected from the commonly accepted norms without necessarily reflecting growth retardation.

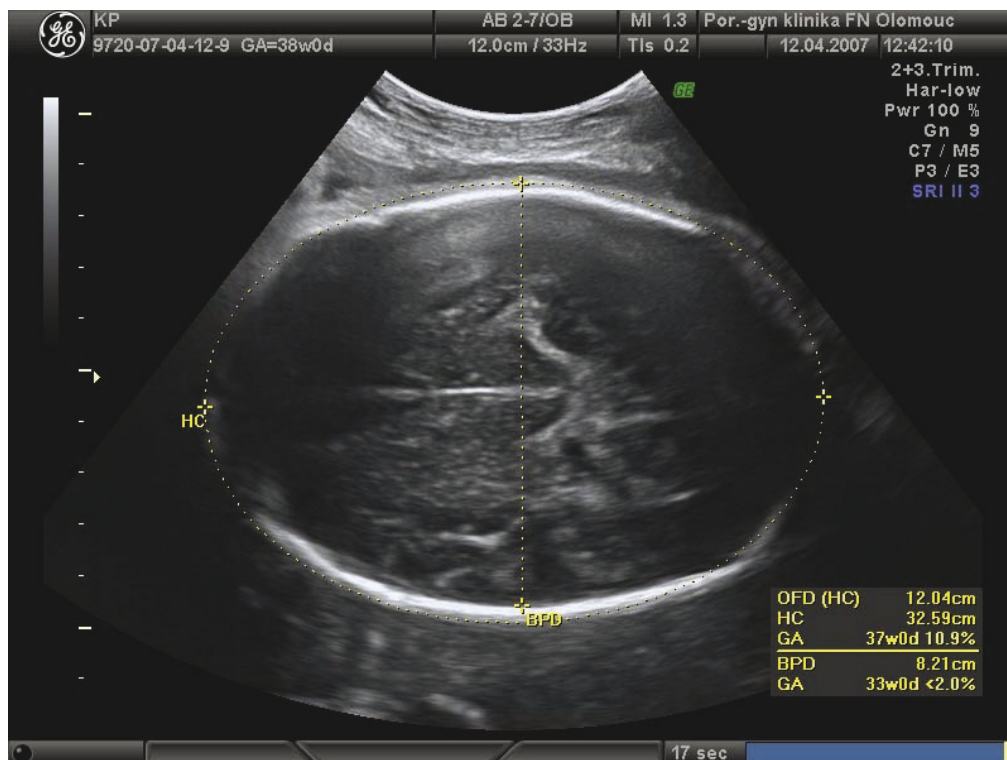


Fig. 3. The “Breech Head” ultrasound scan at 37th week (HC - head circumference - 326 mm - **37w0d**, BPD - biparietal diameter - 82 mm - **33w0d**, OFD - occipitofrontal diameter - 120 mm, OFD/BPD ratio = **1,46**).

It further acknowledges that gestational age prediction from the third trimester BPD is unreliable.

The OFD/BPD ratio was found to be a valuable index for identifying the “breech head”⁷. This ratio is a measure of dolichocephaly and a value above 1.30 is consistent with a small BPD in babies without other evidence of intrauterine growth retardation. An OFD/BPD ratio greater than 1.30 determined by ultrasound in the third trimester should caution the sonographer not to assume that the menstrual dates are incorrect or that the fetus is growth retarded. Third trimester ultrasound measurements of head circumference (HC), femur length (FL) and abdominal circumference (AC) should be used in preference to the biparietal diameter (BPD) for the assessment of fetal growth.

CONCLUSIONS

According to our results, fetuses in the breech position have a significantly lower BPD in comparison with HC or FL. HC and FL parameters correlate with gestational age. In cases of ultrasonographic biometric discrepancy between BPD and FL, the fetal position should be taken into account. Breech presented fetuses have an elongated head shape and ultrasound biometrics should evaluate its circumference (HC). It is important to responsibly interpret the results so as not to stress the expecting mother with suspicions of fetal pathology. Nonetheless, in cases of “breech head”, fetuses should be delivered once full term is reached.

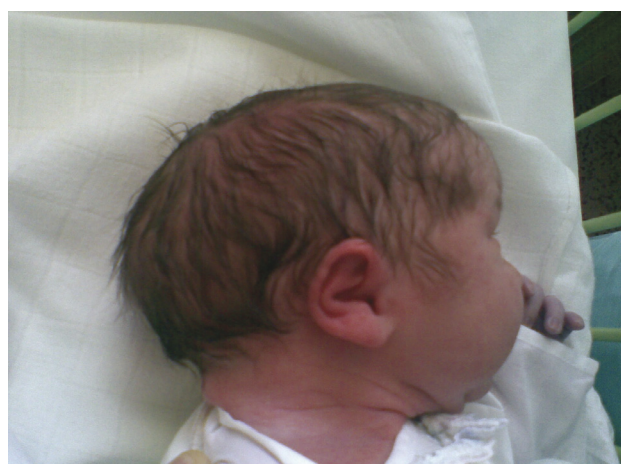

Fig. 4. The “Breech Head”. A relatively long head and a prominent occiput with suboccipital shelving are apparent. Auricular deformation, presumably caused by upward pressure by the fetal shoulder in utero, is also noted.

ABBREVIATIONS:

- AC - abdominal circumference
- BPD - biparietal diameter
- CNS - central nervous system
- CRL - crown-rump length
- FL - femur length
- HC - head circumference
- OFD - occipitofrontal diameter

ACKNOWLEDGEMENTS

This study was supported by the Medical Faculty of Palacký University Olomouc "Safety of Ultrasound in Medicine".

REFERENCES

1. Haberkern CM, Smith DW, Jones KL. The "breech head" and its relevance. *Am J Dis Child* 1979; 133:154-6.
2. Sunderland R. Fetal position and skull shape. *Br J Obstet Gynaecol* 1981; 88:246-9.
3. Hadlock FP, Deter RL, Harrist RB, Park SK. Estimating fetal age: computer-assisted analysis of multiple fetal growth parameters. *Radiology* 1984; 152:497-501.
4. Bromley B, Frigoletto FD Jr, Harlow BL, Evans JK, Benacerraf BR. Biometric measurements in fetuses of different race and gender. *Ultrasound Obstet. Gynecol* 1993; 3:395-402.
5. Lubusky M, Mickova I, Prochazka M, Dzvincuk P, Mala K, Cizek L. Discrepancy of ultrasound biometric parameters of the head (HC - head circumference, BPD - biparietal diameter) and femur length in relation to sex of the fetus and duration of pregnancy. *Ces Gynek* 2006; 71:169-72.
6. Schwärzler P, Bland JM, Holden D, Campbell S, Ville Y. Sex-specific antenatal reference growth charts for uncomplicated singleton pregnancies at 15-40 weeks of gestation. *Ultrasound Obstet Gynecol* 2004; 23:23-9.
7. Kasby CB, Poll V. The breech head and its ultrasound significance. *Br J Obstet Gynaecol* 1982; 89:106-10.
8. Johnsen SL, Wilsgaard T, Rasmussen S, Sollien R, Kiserud T. Longitudinal reference charts for growth of the fetal head, abdomen and femur. *Eur J Obstet Gynecol Reprod Biol* 2006; 127:172-85.
9. Bader B, Graham D, Stinson S. Significance of ultrasound measurements of the head of the breech fetus. *J Ultrasound Med* 1987; 6:437-39.